

## Musculoskeletal Imaging

Jon A. Jacobson, MD  
 Scott Lancaster, MD  
 Amitesh Prasad, MD  
 Marnix T. van Holsbeeck,  
 MD  
 Joseph G. Craig, MB, ChB  
 Patricia Kolowich, MD

### Index terms:

Shoulder, injuries, 414.4813  
 Shoulder, US, 414.1298  
 Tendons, injuries, 414.4813  
 Tendons, US, 414.1298

### Published online

10.1148/radiol.2301020418  
 Radiology 2004; 230:234–242

<sup>1</sup> From the Department of Radiology, University of Michigan Medical Center, Taubman Center, Room 2910-G, 1500 E Medical Center Dr, Ann Arbor, MI 48109-0326 (J.A.J.); Advanced Radiology Services, Spectrum Health, Grand Rapids, Mich (S.L.); Department of Radiology, University of Pittsburgh Medical Center, Pa (A.P.); and Departments of Radiology (M.T.v.H., J.G.C.) and Orthopaedic Surgery (P.K.), Henry Ford Hospital, Detroit, Mich. From the 1999 RSNA scientific assembly. Received April 12, 2002; revision requested June 21; final revision received April 25, 2003; accepted May 20. Address correspondence to J.A.J. (e-mail: [jjacobsn@umich.edu](mailto:jjacobsn@umich.edu)).

### Author contributions:

Guarantors of integrity of entire study, J.A.J., S.L.; study concepts and design, all authors; literature research, J.A.J., S.L., A.P.; clinical studies, J.A.J., M.T.v.H., J.C., P.A.; data acquisition and analysis/interpretation, J.A.J., S.L., A.P.; statistical analysis, J.A.J.; manuscript preparation, definition of intellectual content, editing, revision/review, final version approval, all authors

© RSNA, 2004

# Full-Thickness and Partial-Thickness Supraspinatus Tendon Tears: Value of US Signs in Diagnosis<sup>1</sup>

**PURPOSE:** To determine which US signs are important in the diagnosis of a surgically identifiable supraspinatus tendon tear.

**MATERIALS AND METHODS:** Fifty consecutive ultrasonographic (US) studies of the shoulder in patients who underwent arthroscopic follow-up were retrospectively reviewed by a musculoskeletal radiologist. US images of the supraspinatus tendon were evaluated for tendon nonvisualization, abnormal tendon echogenicity, tendon thinning, greater tuberosity cortical irregularity, cartilage interface sign, joint fluid, and subacromial-subdeltoid bursal fluid. US findings were compared with arthroscopic results. Sensitivity, specificity, positive predictive value, negative predictive value, and accuracy were calculated for each US sign in the diagnosis of full-thickness tendon tear and again for any type of supraspinatus tendon tear.

**RESULTS:** Arthroscopy revealed 21 full-thickness tears, five bursal surface partial-thickness tears, 10 articular surface partial-thickness tears, and 14 patients without tear of the supraspinatus tendon. The presence of greater tuberosity cortical irregularity and joint fluid was most important in the diagnosis of full-thickness supraspinatus tendon tear (sensitivity, 60%; specificity, 100%; positive predictive value, 100%; negative predictive value, 78%; accuracy, 84%). For diagnosis of any type of supraspinatus tendon tear (partial or full thickness), tendon nonvisualization, greater tuberosity cortical irregularity, and cartilage interface sign are most important, although a combination of signs did not improve accuracy.

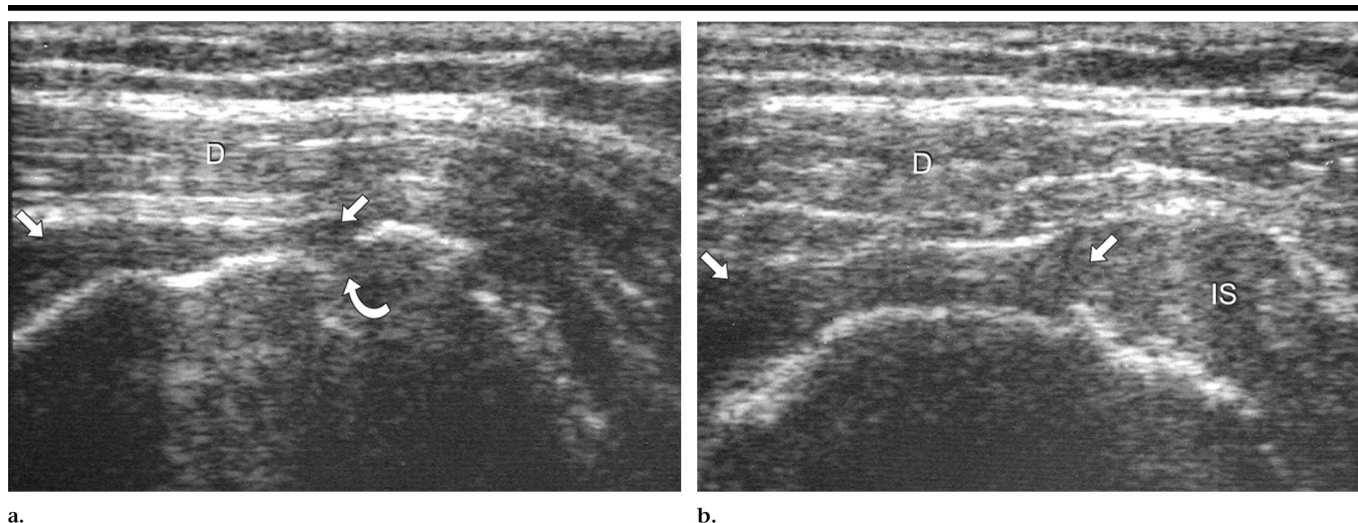
**CONCLUSION:** Secondary US signs, such as greater tuberosity cortical irregularity and joint fluid, are most valuable in the diagnosis of supraspinatus tendon tear.

© RSNA, 2004

Ultrasonography (US) has been established as an effective imaging method in the evaluation of the rotator cuff. Specific US criteria have been used to correctly diagnose rotator cuff tears (1). These include nonvisualization of the rotator cuff or focal tendon defect to indicate a full-thickness tear, flattening of the bursal surface to indicate a bursal side partial-thickness tear, and a distinct hypoechoic or mixed hyper- and hypoechoic defect at the articular surface to indicate an articular side partial-thickness tendon tear (2). Because of the difficulty in diagnosing some rotator cuff tears with US, various associated secondary signs have been described. These include greater tuberosity cortical irregularity (3,4), fluid within the subacromial-subdeltoid bursa (5,6), and joint effusion (5,6). The reported usefulness of each of these signs is variable, and the results are often conflicting.

Relatively less is known about the US appearance of tendinosis. Tendinosis, or tendinopathy, can be defined as tendon degeneration. The term tendinosis is preferred over tendinitis, because eosinophilic, fibrillar, and mucoid degeneration are present, and acute inflammation is typically absent (7). Bachman et al (8) demonstrated that supraspinatus tendon degeneration might appear hypo- or hyperechoic at US. Differentiation from tendon tear may be difficult, as both tendinosis and tendon tear may appear hypoechoic and coexist within the same tendon.

The purpose of our study was to determine which US signs are important in the



**Figure 1.** Full-thickness supraspinatus tendon tear. (a) Longitudinal and (b) transverse US images of the supraspinatus tendon show nonvisualization of the distal supraspinatus tendon and dipping of the deltoid muscle (*D*) into the tendon gap. The hypoechoic area (straight arrows) immediately superficial to the humeral head could represent tapering of the torn distal supraspinatus tendon, complex fluid, and synovial tissue. Note cortical irregularity (curved arrow) of the greater tuberosity and preservation of the infraspinatus tendon (*IS*).

diagnosis of a surgically identifiable supraspinatus tendon tear. US images of the shoulder were retrospectively reviewed in patients with arthroscopically proved diagnoses of full-thickness tear, partial-thickness tear, and no tear of the supraspinatus tendon.

## MATERIALS AND METHODS

### Patients

This study was granted exemption by our Institutional Review Board for both approval and patient consent. Sixty-three consecutive patients who underwent US examination of the shoulder between January 1996 and August 1997 were identified as having undergone shoulder arthroscopy by one orthopedic surgeon. Any subject in whom 300 or more days passed between US examination and arthroscopy was excluded from the study. This resulted in 50 patients (23 women and 27 men) with an average age of 50 years (range, 27–77 years). The average time interval between the US examination and arthroscopy was 122 days (range, 8–275 days).

The original US examinations were performed by one of five musculoskeletal radiologists (J.A.J., M.T.v.H., or J.G.C.) with 3–12 years experience or one dedicated musculoskeletal US technologist with 2 years experience by using 7.5–10.0-MHz linear transducers (HDI 3000, Advanced Technology Laboratories, Bothell, Wash; 5200, Acoustic Imaging, Phoenix, Ariz) and liberal transmission gel in place of a standoff pad. US images included, but

were not limited to, transverse and longitudinal planes relative to the supraspinatus, subscapularis, infraspinatus, and long head of the biceps brachii tendons. The US examinations were ordered and completed as part of the routine clinical investigation of the shoulder, as determined by the orthopedic surgeon. Bursoscopy was performed in conjunction with the arthroscopic examination for evaluation of the supraspinatus tendon. Supraspinatus tendon abnormalities were described at arthroscopy according to the Snyder classification (9) as “A” (articular), “B” (bursal), or “C” (full-thickness or complete tear). A designation of A or B was followed by a number, which indicated grade. Grade 0 was classified as normal, a grade 1 lesion had inflamed synovium and minor (< 1 cm) surface fraying, a grade 2 lesion had actual fiber disruption of more than 1 cm but less than 2 cm, a grade 3 lesion had tendon disruption of 2–3 cm, and a grade 4 lesion had complex tendon disruption, such as flap formation and retraction of more than 3 cm (9).

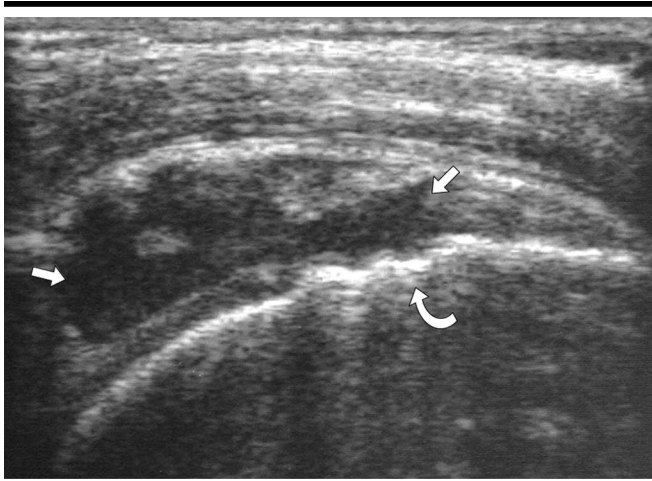
### Image Evaluation

One musculoskeletal radiologist (J.A.J.) who was unaware of the arthroscopic results evaluated all available hard-copy US images of each patient. The supraspinatus tendon was evaluated for primary abnormalities, such as tendon nonvisualization, abnormal tendon echogenicity (predominantly anechoic or hypoechoic

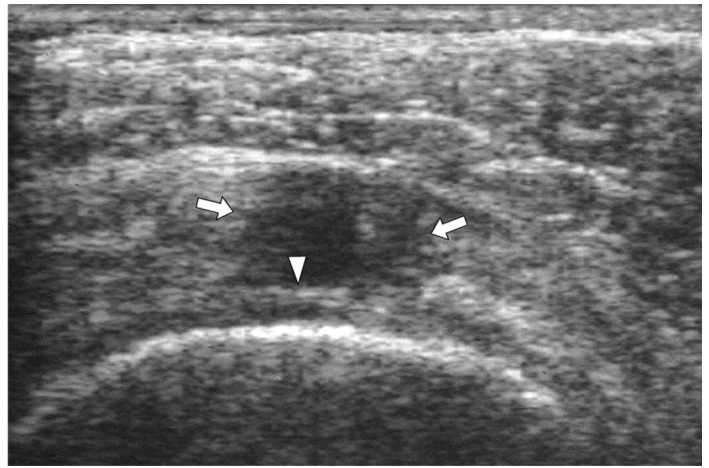
relative to normal hyperechoic tendon), and tendon thinning (flattening or concavity of the normal convex bursal surface). If a focal tendon abnormality was identified, the margins were characterized as either well defined or ill defined, and the extent of the abnormality was characterized as intrasubstance, articular, bursal, or articular surface to bursal surface. The US images were also evaluated for secondary findings, which included cortical irregularity of the greater tuberosity (loss of the normal, smooth hyperechoic surface), the cartilage interface sign (a thin, markedly hyperechoic line at the surface of the hypoechoic, hyaline articular cartilage of the humeral head) (10), joint fluid (any visible anechoic or hypoechoic fluid surrounding the long head of the biceps brachii tendon), and fluid in the subacromial-subdeltoid bursa (greater than 2 mm of anechoic or hypoechoic distention [11], as measured at its point of maximum distention from the acromion to 1–3 cm lateral to the greater tuberosity).

### Arthroscopy and Statistical Evaluation

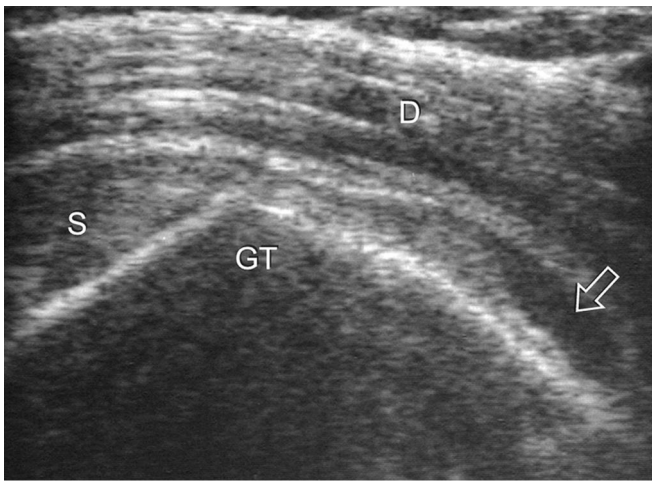
The arthroscopy reports were reviewed by two of the investigators, and results were categorized as full-thickness tear, bursal side partial-thickness tear, articular side partial-thickness tear, and no tendon tear, with respect to the supraspinatus tendon. A grade 1 articular or bursal lesion (minimal fraying and inflamed synovium) was categorized as no tendon



a.



b.



c.

**Figure 2.** Full-thickness supraspinatus tendon tear. (a) Longitudinal and (b) transverse US images of the supraspinatus tendon show abnormal anechoic disruption of the supraspinatus tendon (straight arrows), which extends from the articular to the bursal surface. Note cortical irregularity (curved arrow) of the greater tuberosity and the cartilage interface sign (arrowhead). (c) Longitudinal US image over greater tuberosity (*GT*) shows supraspinatus tendon (*S*) and anechoic fluid (arrow) distending the subacromial-subdeltoid bursa. *D* = deltoid.

tear, similar to what has been previously described in the literature (12). To calculate sensitivity, specificity, positive predictive value, negative predictive value, and accuracy for each US sign, the four categories of possible arthroscopic results were combined to create two columns or categories. In the first calculation, the two categories consisted of full-thickness tendon tear and partial-thickness tendon tear or no tear. In the second calculation, the two categories consisted of full-thickness or partial-thickness tendon tear and no tear. We calculated 95% CIs (Stata; StataCorp, College Station, Tex), except when values were equal to 0% or 100%, in which case we calculated one-sided 97.5% CIs.

Calculation of sensitivity, specificity, positive and negative predictive values, and accuracy was then repeated by using every possible combination of the four secondary US signs (greater tuberosity cortical irregularity, cartilage interface

sign, joint fluid, and subacromial-subdeltoid bursal fluid) and the primary US sign (tendon flattening). This was calculated by combining the possible arthroscopic categories into full-thickness supraspinatus tendon tear versus partial-thickness tendon tear and no tear and both partial- and full-thickness tendon tear versus no tendon tear, similar to what has been mentioned previously.

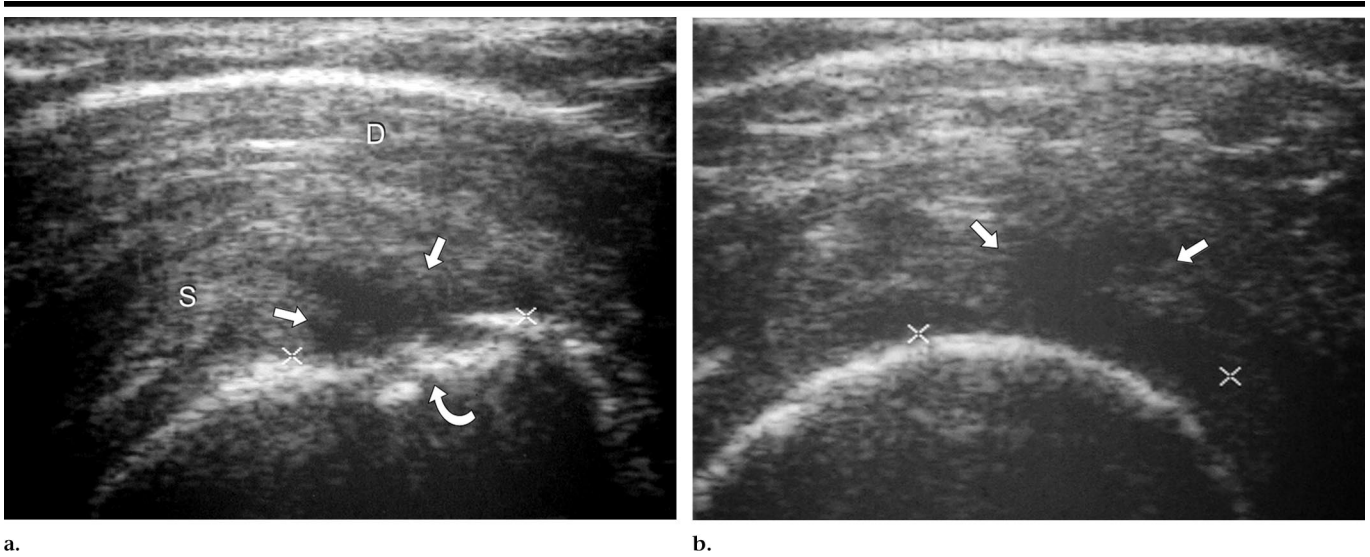
## RESULTS

Arthroscopy revealed 21 patients with full-thickness tears (Figs 1, 2), 10 patients with articular surface partial-thickness tears (grade 2 or greater) (Fig 3), five patients with bursal surface partial-thickness tears (grade 2 or greater) (Fig 4), and 14 patients without tendon tears (Figs 5–7).

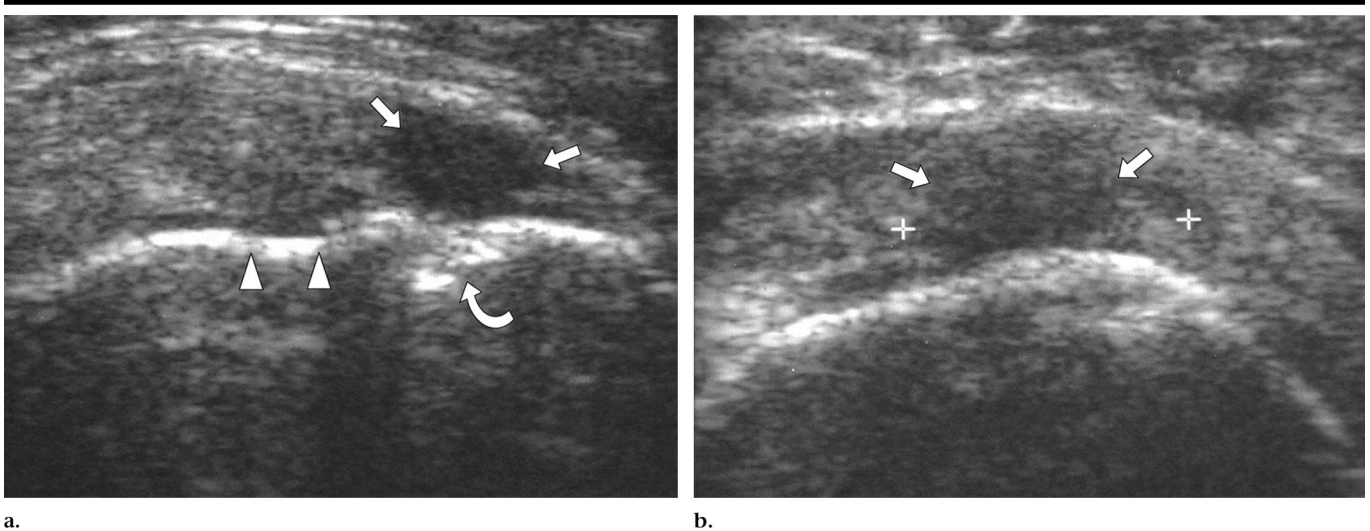
The occurrence of the primary US signs for each arthroscopic result is given in Figure 8. Supraspinatus tendon nonvisualization was present in five (24%) of 21

patients with full-thickness tears, none (0%) of five patients with bursal surface partial-thickness tendon tears, none (0%) of 10 patients with articular surface partial-thickness tendon tears, and none (0%) of 14 patients with tendons without tear. An abnormal hypoechoic area within the supraspinatus tendon was seen in nine (56%) of 16 patients with full-thickness tears where tendon was visible, four (80%) of five patients with bursal surface partial-thickness tears, eight (80%) of 10 patients with articular surface partial-thickness tears, and 10 (71%) of 14 patients with tendons without tear. An abnormal anechoic area within the supraspinatus tendon was seen in seven (44%) of 16 patients with full-thickness tears, one (20%) of five patients with bursal surface partial-thickness tears, two (20%) of 10 patients with articular surface partial-thickness tears, and three (21%) of 14 patients with tendons without tear.

The margins of a focal tendon abnormality were well defined in seven (44%) of 16 patients with full-thickness tears, three (60%) of five patients with bursal surface partial-thickness tears, two (20%) of 10 patients with articular surface partial-thickness tears, and four (31%) of 13 patients with tendons without tear. The margins of a focal tendon abnormality were ill defined in nine (56%) of 16 patients with full-thickness tears, two (40%) of five patients with bursal surface par-



**Figure 3.** Articular side partial-thickness supraspinatus tendon tear. (a) Longitudinal and (b) transverse US images of the supraspinatus tendon show focal, well-defined anechoic disruption (between cursors and straight arrows) at the distal articular surface of the supraspinatus tendon (S). Note cortical irregularity (curved arrow) of the greater tuberosity. D = deltoid.



**Figure 4.** Bursal side partial-thickness supraspinatus tendon tear. US images (a) longitudinal and (b) transverse to the supraspinatus tendon show focal, well-defined anechoic disruption (between cursors and straight arrows) of the distal bursal surface of the supraspinatus tendon. The tendon abnormality extends to the greater tuberosity but does not extend to the articular surface (arrowheads). Note cortical irregularity (curved arrow) of the greater tuberosity.

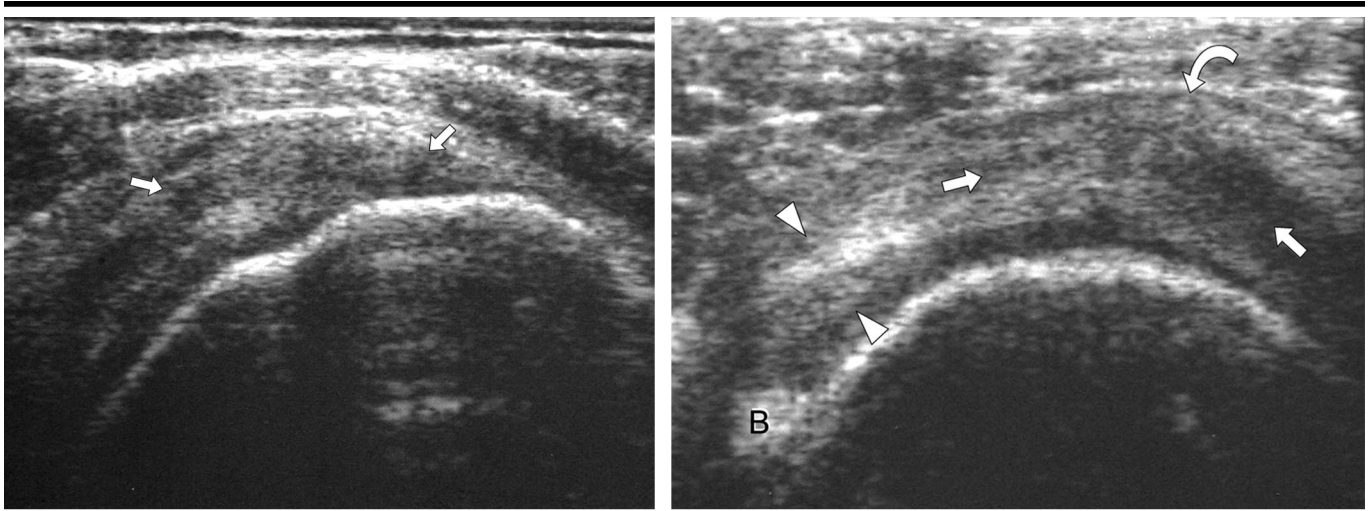
tial-thickness tears, eight (80%) of 10 patients with articular surface partial-thickness tears, and nine (69%) of 13 patients with tendons without tear.

The extent of a focal supraspinatus tendon abnormality was articular surface to bursal surface in 12 (75%) of 16 patients with full-thickness tears, one (20%) of five patients with bursal surface partial-thickness tears, six (60%) of 10 patients with articular surface partial-thickness tears, and three (23%) of 13 patients with tendons without tear. The extent of a focal supraspinatus tendon abnormality was articular in

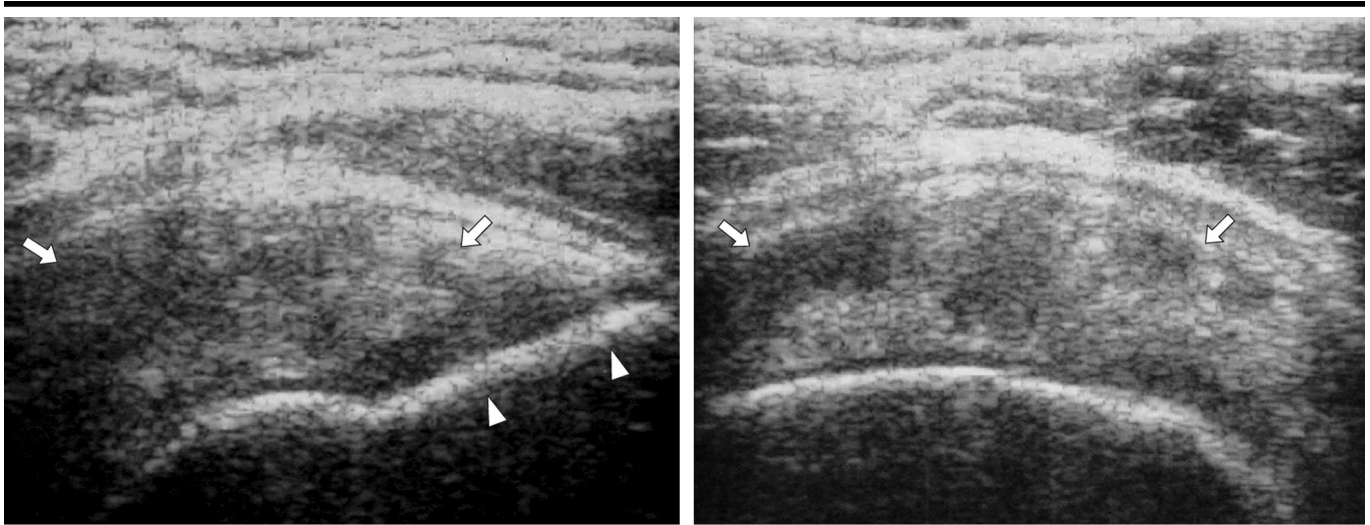
two (13%) of 16 patients with full-thickness tears, one (20%) of five patients with bursal surface partial-thickness tears, two (20%) of 10 patients with articular surface partial-thickness tears, and five (38%) of 13 patients with tendons without tear. The extent of a focal supraspinatus tendon abnormality was bursal in two (13%) of 16 patients with full-thickness tears, two (40%) of five patients with bursal surface partial-thickness tears, none (0%) of 10 patients with articular surface partial-thickness tears, and three (23%) of 13 patients with tendons without tear.

The extent of a focal tendon abnormality was intrasubstance in none (0%) of 16 patients with full-thickness tears, one (20%) of five patients with bursal surface partial-thickness tears, two (20%) of 10 patients with articular surface partial-thickness tears, and two (15%) of 13 patients with tendons without tear.

Supraspinatus tendon thinning was seen in 15 (71%) of 21 patients with full-thickness tears, two (40%) of five patients with bursal surface partial-thickness tears, three (30%) of 10 patients with articular surface partial-thickness tears, and



**Figure 5.** No tendon tear. US images (a) longitudinal and (b) transverse to the supraspinatus tendon show ill-defined heterogeneous hypoechoogenicity (straight arrows), which could represent tendinosis or intrasubstance tear. The anterior aspect of the supraspinatus tendon is of normal thickness (arrowheads) but appears relatively thin due to the thickened area (curved arrow). Note absence of cortical irregularity of the greater tuberosity. *B* = long head of biceps brachii tendon.



**Figure 6.** No tendon tear. US images (a) longitudinal and (b) transverse to the supraspinatus tendon show diffuse, heterogeneous, and ill-defined hypoechoogenicity (arrows), which could represent tendinosis or intrasubstance tear. Note absence of cortical irregularity of the greater tuberosity (arrowheads).

two (14%) of 14 patients with tendons without tear.

The occurrence of the secondary US signs for each arthroscopic result is given in Figure 9. Greater tuberosity cortical irregularity was seen in 18 (86%) of 21 patients with full-thickness tears, two (40%) of five patients with bursal surface partial-thickness tears, five (50%) of 10 patients with articular surface partial-thickness tears, and three (21%) of 14 patients with tendons without tear. Depiction of a cartilage interface was seen in

seven (33%) of 21 patients with full-thickness tears, none (0%) of five patients with bursal surface partial-thickness tears, none (0%) of 10 patients with articular surface partial-thickness tears, and none (0%) of 14 patients with tendons without tear. Joint fluid was identified in 13 (65%) of 20 patients with full-thickness tears, none (0%) of five patients with bursal surface partial-thickness tears, two (20%) of 10 patients with articular surface partial-thickness tears, and one (7%) of 14 patients with tendons without tear.

There was one patient with a full-thickness supraspinatus tear in whom the images did not include the long head of the biceps brachii tendon; therefore, it was not possible to evaluate for joint fluid. Identification of subacromial-subdeltoid bursal fluid was seen in 13 (68%) of 19 patients with full-thickness tears, one (20%) of five patients with bursal surface partial-thickness tears, two (20%) of 10 patients with articular surface partial-thickness tears, and five (36%) of 14 patients with tendons without tear. There

were two patients with a full-thickness supraspinatus tendon tear, in whom the presence or absence of subacromial-subdeltoid fluid could not be assessed.

Sensitivity, specificity, positive and negative predictive values, and accuracy for each US sign in the diagnosis of full-thickness supraspinatus tendon tear versus other diagnoses (partial-thickness tendon tear, tendinosis, or no tendon tear) or any (full- or partial-thickness) tendon tear were calculated. For the diagnosis of full-thickness supraspinatus tendon tear versus other conditions (partial-thickness tear or no tear) (Table 1), the sensitivity, specificity, positive and negative predictive values, and accuracy for tendon nonvisualization were 24% (five of 21), 100% (29 of 29), 100% (five of five), 64% (29 of 45), and 68% (34 of 50). Values for hypoechoic abnormality were 56% (nine of 16), 24% (seven of 29), 29% (nine of 31), 50% (seven of 14), and 36% (16 of 45). Values for anechoic abnormality were 44% (seven of 16), 79% (23 of 29), 54% (seven of 13), 72% (23 of 32), and 67% (30 of 45). Values for tendon abnormality with well-defined margins were 44% (seven of 16), 68% (19 of 28), 44% (seven of 16), 68% (19 of 28), and 59% (26 of 44). Values for tendon abnormality with ill-defined margins were 56% (nine of 16), 32% (nine of 28), 32% (nine of 28), 56% (nine of 16), and 41% (18 of 44). Values for bursal to articular surface abnormality were 75% (12 of 16), 64% (18 of 28), 55% (12 of 22), 82% (18 of 22), and 68% (30 of 44). Values for articular surface abnormality were 12% (two of 16), 71% (20 of 28), 20% (two of 10), 59% (20 of 34), and 50% (22 of 44). Values for bursal surface abnormality were 12% (two of 16), 82% (23 of 28), 29% (two of seven), 62% (23 of 37), and 57% (25 of 44). Values for intrasubstance abnormality were 0% (zero of 16), 82% (23 of 28), 0% (zero of five), 59% (23 of 39), and 52% (23 of 44). Values for tendon thinning were 71% (15 of 21), 76% (22 of 29), 68% (15 of 22), 79% (22 of 28), and 74% (37 of 50). Values for cortical irregularity were 86% (18 of 21), 66% (19 of 29), 64% (18 of 28), 86% (19 of 22), and 74% (37 of 50). Values for cartilage interface sign were 33% (seven of 21), 100% (29 of 29), 100% (seven of seven), 67% (29 of 43), and 72% (36 of 50). Values for joint fluid were 65% (13 of 20), 90% (26 of 29), 81% (13 of 16), 79% (26 of 33), and 80% (39 of 49). Values for bursal fluid were 68% (13 of 19), 72% (21 of 29), 62% (13 of 21), 78% (21 of 27), and 71% (34 of 48).

For the diagnosis of any (full- or partial-thickness) supraspinatus tendon tear

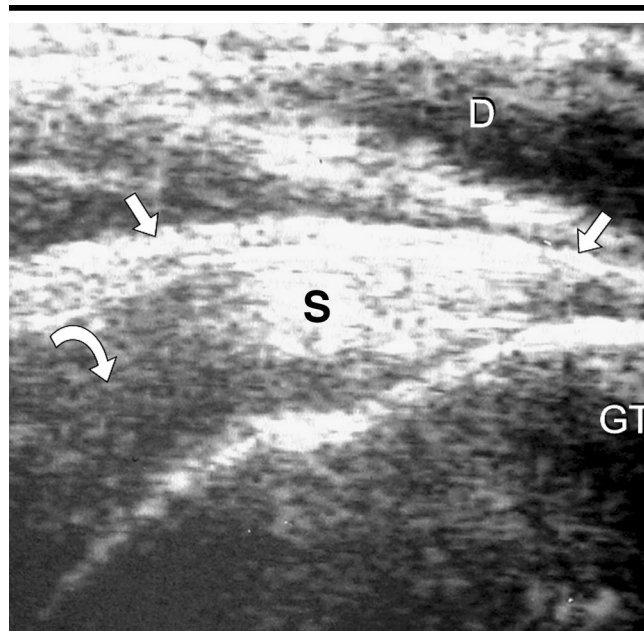


Figure 7. Normal supraspinatus tendon. US image longitudinal to the supraspinatus tendon (S) shows normal hyperechoic fibrillar echotexture (straight arrows). Note artifactual hypoechoogenicity (anisotropy) (curved arrow) where the tendon fibers are oblique to the ultrasound beam. D = deltoid, GT = greater tuberosity.

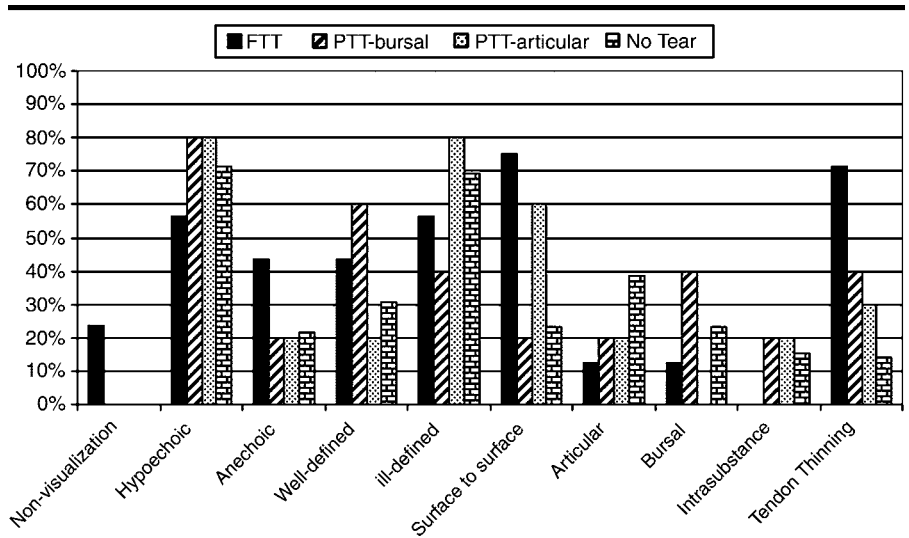
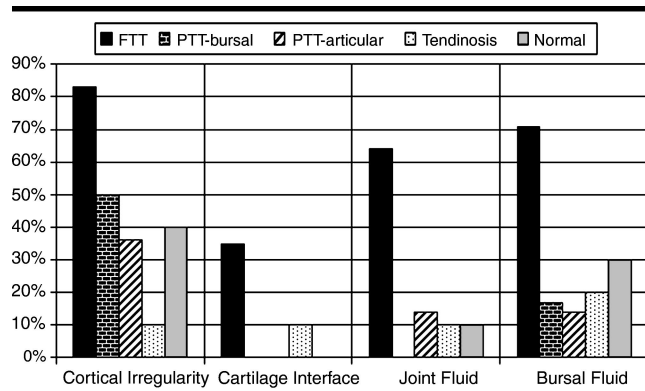


Figure 8. Percent occurrence of each primary US sign for each arthroscopic result. FTT = full-thickness supraspinatus tendon tear, PTT-bursal = bursal side partial-thickness tear, PTT-articular = articular side partial-thickness tear.

versus no tendon tear (Table 2), the sensitivity, specificity, positive predictive value, negative predictive value, and accuracy were calculated. Values for absent tendon were 14% (five of 36), 100% (14 of 14), 100% (five of five), 31% (14 of 45), and 38% (19 of 50). Values for hypoechoic abnormality were 68% (21 of 31), 29% (four of 14), 68% (21 of 31), 29% (four of 14), and 56% (25 of 45). Values

for anechoic abnormality were 32% (10 of 31), 79% (11 of 14), 77% (10 of 13), 34% (11 of 32), and 47% (21 of 45). Values for tendon abnormality with well-defined margins were 39% (12 of 31), 69% (nine of 13), 75% (12 of 16), 32% (nine of 28), and 48% (21 of 44). Values for tendon abnormality with ill-defined margins were 61% (19 of 31), 31% (four of 13), 68% (19 of 28), 25% (four of 16),



**Figure 9.** Percent occurrence of each secondary US sign for each arthroscopic result. *FTT* = full-thickness supraspinatus tendon tear, *PTT-bursal* = bursal side partial-thickness tear, *PTT-articular* = articular side partial-thickness tear.

and 52% (23 of 44). Values for bursal to articular surface abnormality were 61% (19 of 31), 77% (10 of 13), 86% (19 of 22), 45% (10 of 22), and 66% (29 of 44). Values for articular surface abnormality were 16% (five of 31), 62% (eight of 13), 50% (five of 10), 24% (eight of 34), and 30% (13 of 44). Values for bursal surface abnormality were 13% (four of 31), 77% (10 of 13), 57% (four of seven), 27% (10 of 37), and 32% (14 of 44). Values for intrasubstance abnormality were 10% (three of 31), 85% (11 of 13), 60% (three of five), 28% (11 of 39), and 32% (14 of 44). Values for tendon thinning were 56% (20 of 36), 86% (12 of 14), 91% (20 of 22), 43% (12 of 28), and 64% (32 of 50). Values for cortical irregularity were 69% (25 of 36), 79% (11 of 14), 89% (25 of 28), 50% (11 of 22), and 72% (36 of 50). Values for cartilage interface sign were 19% (seven of 36), 100% (14 of 14), 100% (seven of seven), 33% (14 of 43), and 42% (21 of 50). Values for joint fluid were 43% (15 of 35), 93% (13 of 14), 94% (15 of 16), 39% (13 of 33), and 57% (28 of 49). Values for bursal fluid were 47% (16 of 34), 64% (nine of 14), 76% (16 of 21), 33% (nine of 27), and 52% (25 of 27).

The US signs of tendon thinning, greater tuberosity cortical irregularity, cartilage interface sign, joint fluid, and subacromial-subdeltoid bursal fluid were reevaluated to determine the effect of combining the US signs. Both tendon thinning and cortical irregularity of the greater tuberosity were found in 14 (67%) of 21 patients, and a combination of tendon thinning and joint and bursal fluid was present in 12 (67%) of 18 patients with full-thickness supraspinatus tendon tears; however, cortical irregularity alone was found in 18 (86%) of 21 patients with full-thickness tears. As each addi-

tional US sign was added, the sensitivity for diagnosis of full-thickness tendon tear versus diagnosis of another abnormality (partial-thickness tear or no tendon tear) decreased. For example, all five US signs were present in only two (11%) of 18 patients with full-thickness tears. A similar finding occurred with the diagnosis of any type of tendon tear versus no tendon tear. With regard to the diagnosis of full-thickness supraspinatus tendon tear versus other conditions (partial-thickness tear or no tendon tear), by simply pairing any two of the five US signs, the specificity increased to at least 86%; however, this was still lower than the specificity of 100% that was obtained by using the single diagnostic sign of absent tendon or cartilage interface sign.

In the diagnosis of full-thickness tendon tear versus other conditions (partial-thickness tear, tendinosis, or no tear), we found the combination of tendon thinning and cortical irregularity of the greater tuberosity and joint fluid had 60% sensitivity, 100% specificity, 100% positive predictive value, 78% negative predictive value, and 84% accuracy. These results are higher than those for any single US sign alone. In the diagnosis of any type of tendon tear (full or partial-thickness) versus no tendon tear, we found the combination of tendon thinning and cortical irregularity of the greater tuberosity had 47% sensitivity, 93% specificity, 94% positive predictive value, 41% negative predictive value, and 60% accuracy. The accuracy of combining these US signs was less than several of the single primary and secondary US signs (Table 2).

## DISCUSSION

With regard to primary US signs in evaluation of the supraspinatus tendon, non-

visualization of the supraspinatus tendon was found in five (24%) of 21 patients with full-thickness tears and in no patients with partial-thickness or no tendon tear. Tendon nonvisualization is the single primary US finding that best predicts full-thickness tendon tear, similar to what has been described previously (1). Abnormal hypoechoic or anechoic areas within the tendon were of limited value in predicting a tear at arthroscopy or bursoscopy, as this finding was present in patients with and those without a tendon tear. Most tendon tears were hypoechoic with ill-defined margins. The presence of abnormal hypoechoic (71%) or anechoic (21%) areas in patients without tendon tear can be attributed to intrasubstance tear or tendinosis not visible at arthroscopy or bursoscopy. The possibility of anisotropy as a cause of abnormal tendon hypoechogenicity is less likely, as only tendon segments perpendicular to the ultrasound beam are assessed for abnormality, and the individuals acquiring the US images were experienced in musculoskeletal US and were trained to eliminate anisotropy before imaging an area of low echogenicity. A normal hyperechoic tendon was sufficient for exclusion of tendon abnormalities of any kind, although this was seen in only one patient. None of our patients had an abnormal hyperechoic area.

With regard to location of a tendon abnormality, an abnormal hypoechoic or anechoic area extended from the bursal to the articular surface in 12 (75%) of 16 patients with full-thickness tears, and the tendon abnormality was isolated to the bursal surface in two (40%) of five patients with bursal side partial-thickness tears; however, only two (20%) of 10 patients with articular side partial-thickness tears had a tendon abnormality isolated to the articular surface on US images. Surface extension of abnormal tendon echogenicity did not allow differentiation between various tendon tears and no tendon tear. Tendon thinning was seen in 15 (71%) of 21 patients with full-thickness tears, two (40%) of five patients with bursal side partial-thickness tears, three (30%) of 10 patients with articular side partial-thickness tears, and two (14%) of 14 patients without tendon tear. The cause of tendon thinning in these two patients without tendon tear is uncertain. Intrasubstance tears that produce tendon thinning may not be depicted at arthroscopy or bursoscopy. Additionally, apparent thinning of the supraspinatus may be encountered if focal hyperechoic subacromial-subdeltoid bursal thicken-

**TABLE 1**  
**Diagnosis of Full-Thickness Supraspinatus Tendon Tear versus Partial-Thickness Tendon Tear and No Tendon Tear with US**

US Findings	Sensitivity	Specificity	Positive Predictive Value	Negative Predictive Value	Accuracy
Tendon nonvisualization	24 (8, 47)	100 (88, 100)	100 (48, 100)	64 (49, 78)	68 (53, 81)
Echogenicity					
Hypoechoic	56 (30, 80)	24 (10, 44)	29 (14, 48)	50 (23, 77)	36 (22, 51)
Anechoic	44 (20, 70)	79 (60, 92)	54 (25, 81)	72 (53, 86)	67 (51, 80)
Margins					
Well defined	44 (20, 70)	68 (48, 84)	44 (20, 70)	68 (48, 84)	59 (43, 74)
Ill defined	56 (30, 80)	32 (16, 52)	32 (16, 52)	56 (30, 80)	41 (26, 57)
Location					
Surface to surface	75 (48, 93)	64 (44, 81)	55 (32, 76)	82 (60, 95)	68 (52, 81)
Articular	12 (2, 38)	71 (51, 87)	20 (3, 56)	59 (41, 75)	50 (35, 65)
Bursal	12 (2, 38)	82 (63, 94)	29 (4, 71)	62 (45, 78)	57 (41, 72)
Intrasubstance	0 (0, 21)	82 (63, 94)	0 (0, 52)	59 (42, 74)	52 (37, 68)
Tendon thinning	71 (48, 89)	76 (57, 90)	68 (45, 86)	79 (59, 92)	74 (60, 85)
Secondary signs					
Cortical irregularity	86 (64, 97)	66 (46, 82)	64 (44, 81)	86 (65, 97)	74 (60, 85)
Cartilage interface	33 (15, 57)	100 (88, 100)	100 (59, 100)	67 (51, 81)	72 (58, 84)
Joint fluid	65 (41, 85)	90 (79, 100)	81 (54, 96)	79 (61, 91)	80 (66, 90)
Bursal fluid	68 (43, 87)	72 (53, 87)	62 (38, 82)	78 (58, 91)	71 (56, 83)

Note.—Data are percentages. Values in parentheses are 95% CIs or one-sided 97.5% CIs if value is 0% or 100%.

**TABLE 2**  
**Diagnosis of Partial- or Full-Thickness Supraspinatus Tendon Tear versus No Tendon Tear with US**

US Findings	Sensitivity	Specificity	Positive Predictive Value	Negative Predictive Value	Accuracy
Tendon nonvisualization	14 (5, 29)	100 (77, 100)	100 (48, 100)	31 (18, 47)	38 (25, 53)
Echogenicity					
Hypoechoic	68 (49, 83)	29 (8, 58)	68 (49, 83)	29 (8, 58)	56 (40, 70)
Anechoic	32 (17, 51)	79 (49, 95)	77 (46, 95)	34 (19, 53)	47 (32, 62)
Margins					
Well defined	39 (22, 58)	69 (39, 91)	75 (48, 93)	32 (16, 52)	48 (32, 63)
Ill defined	61 (42, 78)	31 (9, 61)	68 (48, 84)	25 (7, 52)	52 (37, 68)
Location					
Surface to surface	61 (42, 78)	77 (46, 95)	86 (65, 97)	45 (24, 68)	66 (50, 80)
Articular	16 (5, 34)	62 (32, 86)	50 (19, 81)	24 (11, 41)	30 (17, 45)
Bursal	13 (4, 30)	77 (46, 95)	57 (18, 90)	27 (14, 44)	32 (19, 48)
Intrasubstance	10 (2, 26)	85 (55, 98)	60 (15, 95)	28 (15, 45)	32 (19, 48)
Tendon thinning	56 (38, 72)	86 (57, 98)	91 (71, 99)	43 (24, 63)	64 (49, 77)
Secondary signs					
Cortical irregularity	69 (52, 84)	79 (49, 95)	89 (72, 98)	50 (28, 72)	72 (58, 84)
Cartilage interface	19 (8, 36)	100 (77, 100)	100 (59, 100)	33 (19, 49)	42 (28, 57)
Joint fluid	43 (26, 61)	93 (78, 100)	94 (70, 100)	39 (23, 58)	57 (42, 71)
Bursal fluid	47 (30, 65)	64 (35, 87)	76 (53, 92)	33 (17, 54)	52 (37, 67)

Note.—Data are percentages. Values in parentheses are 95% CIs or one-sided 97.5% CIs if value is 0% or 100%.

ing is mistaken for tendon fibers or if the adjacent tendon is thickened.

Evaluation of the secondary US signs (greater tuberosity cortical irregularity, cartilage interface sign, joint fluid, and subacromial-subdeltoid bursal fluid) shows that with the exception of bursal fluid, each is present more often in patients with a tendon tear than in patients with no tendon tear. The presence of any secondary US sign in the group of patients without tendon tear at arthroscopy or bursoscopy may be attributed to intra-substance tendon tears or degeneration not visible at arthroscopy or bursoscopy, as well as shoulder abnormalities not involving the supraspinatus tendon.

The importance of cortical irregularity of the greater tuberosity as an indicator of rotator cuff tears has been debated (3,4,13). We found cortical irregularity, as shown with US, to be present in 18 (86%) of 21 patients with full-thickness supraspinatus tendon tears, two (40%) of five patients with bursal side partial-thickness tears, five (50%) of 10 patients with articular side partial-thickness tears, and three (21%) of 14 patients without tendon tear. We found this sign to be very important, as it had the highest sensitivity and negative predictive value in the diagnosis of any type of tendon tear.

A thin echogenic line at the interface of hypoechoic hyaline articular cartilage

of the humeral head and the adjacent rotator cuff (the cartilage interface sign) (10) was seen in seven (33%) of 21 patients with full-thickness tears and was not seen in patients with any other conditions. This sign had 100% specificity and 100% positive predictive value in the diagnosis of full-thickness tendon tear or any tendon tear; however, sensitivities remained low. We recognize that a hyperechoic interface between the hyaline cartilage and the overlying rotator cuff can be depicted normally; therefore, we acknowledge that this sign is subjective. A positive cartilage interface sign should be reserved for patients in whom the interface is markedly hyperechoic. This

finding is often more conspicuous when there is hypoechoic or anechoic fluid overlying the articular cartilage.

Similar to the importance of greater tuberosity cortical irregularity, the importance of joint fluid and fluid in the subacromial-subdeltoid bursa as an indicator of rotator cuff tear is debated (5,6,14,15). We found joint fluid in 13 (65%) of 20 patients with full-thickness supraspinatus tendon tears, no (0%) of five patients with bursal side partial-thickness tears, two (2%) of 10 patients with articular side partial-thickness tears, and one (7%) of 14 patients without tendon tear. With regard to bursal fluid, this finding was present in 13 (68%) of 19 patients with full-thickness tendon tears, one (20%) of five patients with bursal side partial-thickness tendon tears, two (20%) of 10 patients with articular side partial-thickness tendon tears, and five (36%) of 14 patients without a tendon tear. The relative high percentage of bursal fluid in these latter patients can be explained by possible isolated bursitis or fluid secondary to shoulder impingement.

In the 14 patients without tendon tear in this study, 10 (71%) had abnormal hypoechoic areas, and three (21%) had abnormal anechoic areas. While the cause of this abnormal tendon echogenicity is unknown, it is possible that these findings represent tendinosis; however, this cannot be confirmed, as arthroscopy and bursoscopy are insensitive in the diagnosis of tendinosis and intrasubstance tendon tears. The relative low percentage of tendon thinning (14%) and cortical irregularity (21%) compared with patients with tendon tears suggests the majority of these patients have tendinosis. No patients in this study had abnormal increased areas of tendon echogenicity, which suggests that this may not be a prevalent finding in tendinosis.

In the diagnosis of full-thickness supraspinatus tendon tear versus other conditions (partial-thickness tendon tear or no tendon tear), the following conclusions can be made. Cortical irregularity of the greater tuberosity is the most sensitive US sign (86%). Tendon nonvisualization and cartilage interface sign are the most specific signs (100%). Tendon nonvisualization and the cartilage interface sign have the highest positive predictive values (100%). Greater tuberosity

cortical irregularity has the highest negative predictive value (86%), while overall, the presence of joint effusion is most accurate (80%). In other words, no one US sign is very helpful. We found that a combination of secondary US signs (greater tuberosity cortical irregularity and joint fluid) is, in fact, most helpful (sensitivity, 60%; specificity, 100%; positive predictive value, 100%; negative predictive value, 78%; accuracy, 84%).

In the diagnosis of partial- or full-thickness supraspinatus tendon tear versus no tendon tear, greater tuberosity cortical irregularity is most sensitive (69%), tendon nonvisualization and cartilage interface sign are most specific (100%) and have the highest positive predictive values (100%), and greater tuberosity irregularity has the highest negative predictive value (50%) and highest accuracy (72%). We found that a combination of US signs did not improve accuracy in the detection of full-thickness tear or any other tear when compared with any single primary or secondary US sign.

The limitations of this study include the retrospective review of US images, which relies on the technique of the individual performing the US examination and the diligence of that individual to document adequately the US findings on static images. Additionally, it was not possible to categorize the primary and secondary US signs as independent observations, as many of the findings were present on the same image. Our use of distention of the long head of the biceps brachii tendon sheath as an indicator of joint fluid is another limitation, as it is possible that not all cases of joint fluid will distend this tendon sheath, and true tenosynovitis may simulate joint fluid on static US images. Selection bias may be present, as patients with abnormal US findings may be more likely to undergo arthroscopy. The use of arthroscopy and bursoscopy can be viewed as a limitation as well, as intrasubstance tendon abnormalities cannot be diagnosed.

In conclusion, in the diagnosis of full-thickness supraspinatus tear, the secondary US signs of greater tuberosity cortical irregularity and joint effusion are most helpful. In the diagnosis of partial-thickness supraspinatus tear, tendon nonvisualization, greater tuberosity cortical irregularity, and cartilage interface sign are important, although a combination of US signs did not improve accuracy.

## References

- Weiner SN, Seitz WH. Sonography of the shoulder in patients with tears of the rotator cuff: accuracy and value for selecting surgical options. *AJR Am J Roentgenol* 1993; 160:103-107.
- Teefey SA, Hasan SA, Middleton WD, Patel M, Wright R, Yamaguchi K. Ultrasonography of the rotator cuff: a comparison of ultrasonographic and arthroscopic findings in one hundred consecutive cases. *J Bone Joint Surg Am* 2000; 82:498-504.
- Wohlwend JR, van Holsbeek M, Craig J, et al. The association between irregular greater tuberosities and rotator cuff tears: a sonographic study. *AJR Am J Roentgenol* 1998; 171:229-233.
- Huang LF, Rubin DA, Britton CA. Greater tuberosity changes as revealed by radiography: lack of clinical usefulness in patients with rotator cuff disease. *AJR Am J Roentgenol* 1999; 172:1381-1388.
- Hollister MS, Mack LA, Patten RM, Winter TC, Matsen FA, Veith RR. Association of sonographically detected subacromial/subdeltoid bursal effusion and intraarticular fluid with rotator cuff tear. *AJR Am J Roentgenol* 1995; 165:605-608.
- Arslan G, Apaydin A, Kabaalioglu A, Sindel T, Lüleci E. Sonographically detected subacromial/subdeltoid bursal effusion and biceps tendon sheath fluid: reliable signs of rotator cuff tear? *J Clin Ultrasound* 1999; 27:335-339.
- Kjellin K, Ho CP, Cervilla V, et al. Alterations in the supraspinatus tendon at MR imaging: correlation with histopathologic findings in cadavers. *Radiology* 1991; 181:837-841.
- Bachmann GF, Melzer C, Heinrichs CM, Möhring B, Rominger MB. Diagnosis of rotator cuff lesions: comparison of US and MRI on 38 joint specimens. *Eur Radiol* 1997; 7:192-197.
- Snyder SJ, Pachelli AF, Del Pizzo W, Friedman MJ, Ferkel RD, Pattee G. Partial thickness rotator cuff tears: results of arthroscopy treatment. *Arthroscopy* 1991; 7:1-7.
- van Holsbeek M, Introcaso JH, Kolowich PA. Sonography of tendons: patterns of disease. *Instr Course Lect* 1994; 43:475-481.
- van Holsbeek M, Strouse PJ. Sonography of the shoulder: evaluation of the subacromial-subdeltoid bursa. *AJR Am J Roentgenol* 1993; 160:561-564.
- Ellman H. Diagnosis and treatment of incomplete rotator cuff tears. *Clin Orthop* 1990; 254:64-75.
- Jiang Y, Zhao J, van Holsbeek MT, Flynn MJ, Ouyang X, Genant HK. Trabecular microstructure and surface changes in the greater tuberosity in rotator cuff tears. *Skeletal Radiol* 2002; 31:522-528.
- Monu JUV, Pruet S, Vanarthos WJ, Pope TL. Isolated subacromial bursal fluid on MRI of the shoulder in symptomatic patients: correlation with arthroscopic findings. *Skeletal Radiol* 1994; 23:529-533.
- Schweitzer ME, Magbalon MJ, Fenlin JM, Frieman BG, Ehrlich S, Epstein RE. Effusion criteria and clinical importance of glenohumeral joint fluid: MR imaging evaluation. *Radiology* 1995; 194:821-824.