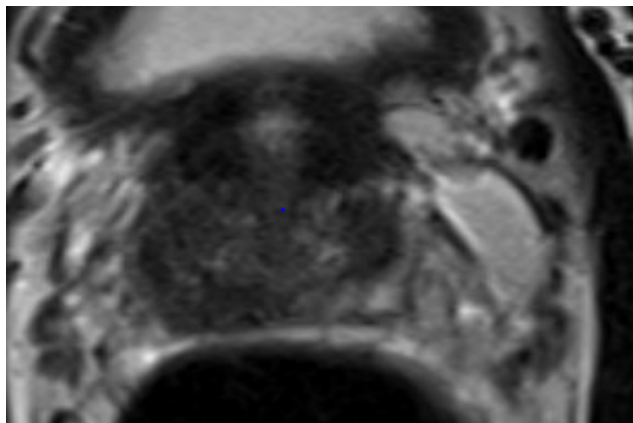


## Case of the Month

# Salvage Focal Cryo-Ablation Combined with Robotic Seminal Vesiculectomy Following Local Recurrence of Prostate Cancer Following Primary Partial Gland Cryo-Ablation

### Case Presentation

A man in his late fifties presented with an elevated and rising PSA. His PSA had increased to 5.5 ng/mL. An MRI demonstrated a PIRADS 4 region of interest (ROI) at the right peripheral zone mid prostate extending to the base (Figure 1). A magnetic resonance fusion targeted biopsy (MRFTB) coupled with a 12-core systematic biopsy (SB) demonstrated a Gleason Grade Group (GGG) 3 cancer in only 1 targeted core obtained from the MRI ROI. The patient denied a family history of prostate cancer. His baseline SHIM was 25, and his IPSS was 3.



**Figure 1.** 14 x 9 PIRADS 3 lesion in the right peripheral zone involving the lateral base and mid prostate. The T2 sequence is shown.

### Management

The patient was counseled regarding active surveillance, partial gland cryo-ablation (PGCA), radical prostatectomy (RP), and radiation therapy (RT). He was adamant about preserving sexual function, avoiding incontinence, and not receiving androgen deprivation therapy. We agreed that active surveillance was not a reasonable option based on his young age and extent of disease. He elected PGCA, which was performed under general anesthesia as an outpatient procedure in 2022. He regained sexual function in a week. Our surveillance protocol at the time included PSA every 6 months and mpMRI and MRFTB + SB at 6 and 24 months.

## Case of the Month

The patient's 6-month post ablation PSA was 1.2 ng/mL. There was a suspicious in-field recurrence on the 6-month MRI. All 4 biopsies of the ablation zone, 4 biopsies of the suspicious MRI ROI, and 12 SBs were negative for cancer.

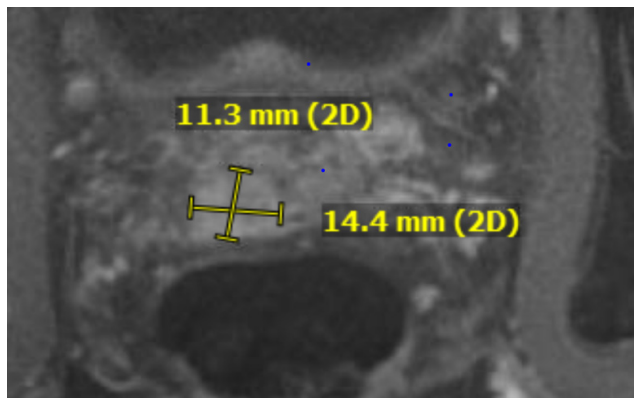
The patient's PSAs post ablation were:

6 months	1.2 ng/mL
9 months	1.6 ng/mL
12 months	3.4 ng/mL
15 months	2.6 ng/mL

The patient's PSA progressively rose as shown above and a 24-month mpMRI showed a suspicious ROI involving the right seminal vesicle (SV) and the base of the prostate (Figure 2)

24 months	4.4 ng/mL
27 months	7.2 ng/mL
30 months	0.9 ng/mL (post salvage treatment)

A biopsy of the right SV and the SBs showed a GGG3 involving the right SV and the right base of the prostate. All other SBs were negative. A prostate-specific membrane antigen (PSMA) PET CT scan showed no nodal or systemic metastasis. The management recommendations were a salvage RP or RT. Again, the patient was adamant about preserving quality of life. We offered the option of salvage focal cryo-ablation (SFCA) of the right base of the prostate and the right SV together with robotic seminal vesiculectomy (rSV). The patient chose SFCA with rSV, which was performed towards the end of 2022.



**Figure 2.** Dynamic contrast enhancement sequence of mpMRI, showing highly suspicious recurrence of in the right SV.

Did they receive ADT. Was it bx proven SV invasion

### Salvage Focal Cryoablation

Following induction of general anesthesia, the patient was placed in the dorsal lithotomy position. Endocare V-Probe cryoprobes were advanced into the prostate transperineally to create a confluent treatment volume encompassing the intraprostatic recurrent disease and the base of the right SV. Thermocouples were placed at the treatment boundaries to provide intraoperative temperature assessment as well as critical structures. An additional thermocouple was advanced between 1 cm and 2 cm beyond the junction of the prostate base and the SV. Cystoscopy was performed to ensure that there was no needle placement within the urethra or the bladder and a warming urethral catheter was then advanced into the bladder over a guidewire.

## Case of the Month

Using the Endocare Cryocare system, 2 freeze-thaw cycles were performed with the treatment volume assessed in real time via ultrasound and temperature monitoring. Following completion of the final thaw procedure, all probes except the thermocouple at the base of the prostate were removed. A 16 Fr Council Tip catheter was inserted over the wire.

### Robotic Seminal Vesiculectomy

Attention was then turned to the rSV. Ports were placed in 5-wide row at the level of the umbilicus. In a fashion similar to a posterior robotic prostatectomy approach, the peritoneum anterior to the rectum was incised. The right SV was identified and placed on traction. Clips and bipolar cautery were employed to ligate the vascular pedicle. The anterior right SV near the base of the prostate was dissected with monopolar cautery. As the junction between the right SV and the prostate was reached, a bedside assistant manipulated the remaining thermocouple embedded in the right SV. Visualization of the thermocouple ensured complete excision of the right SV. The thermocouple was withdrawn and the right SV was amputated from the base of the prostate with monopolar cautery and sharp dissection. The SV was placed in a specimen bag for biopsy, and hemostasis was achieved.

The patient was discharged with a Foley catheter on the first postoperative day. He performed a trial void on the fourth postoperative day. The patient reported having sexual intercourse 1 week after catheter removal and never experiencing incontinence.

At 3 months post salvage treatment, the patient's PSA was 0.89 ng/mL. PSA and mpMRI will be performed at 6 months post salvage treatment.

### Discussion

The standard options for managing local recurrent prostate cancer (LRPC) following radiation therapy are salvage ablation or RP. Salvage RP is associated with significant morbidity. mpMRI and targeted biopsy have enabled identification of site(s) of clinically significant prostate cancer following radiation therapy. In select cases where LRPC is localized to an index lesion, SFCA offers an alternative to salvage RP and whole-gland cryoablation. Reports of preliminary experience with SFCA indicate good early oncological control with minimal complications. In the setting of LRPC involving the SV, SFCA alone is unlikely to achieve local disease control.

Ward et al. reported a series of primary salvage whole-gland cryotherapy for clinically advanced T3 disease, which included the SV in the treatment planning.<sup>1</sup> The biochemical disease-free survival rate was 51.9% at 60 months, with incontinence and rectourethral fistula rates of 2.6% and 1.1%, respectively.

Langley et al. have published the only series of rSV in men with LRPC.<sup>2</sup> Seventeen men underwent bilateral rSV following brachytherapy for LRPC involving the SV. The majority of the cases presented with bilateral involvement of the SV. It is not surprising that without treating the adjacent prostate, 41% had positive surgical margins and the biochemical disease-free survival rate at 3 years was only 53%. The high recurrence rate reported by Langley et al. suggests that rSV should be performed together with ablation.

The high rates of LRPC involving the SV following salvage ablation alone or rSV alone following radiation therapy suggest that the optimal management in this setting would be a combination of ablation and rSV.

## Case of the Month

We will be reporting 5 cases in which we performed a combination of SFCA and rSV for LRPC involving the SV following radiation therapy and 2 cases in which we performed the same procedures following focal therapy. The case described here is 1 of these 7 cases. Although very limited, our experience to date suggests that SFCA combined with rSV is a reasonable salvage option for men with LRPC limited to the SV and the adjacent prostate following focal therapy.

### References

1. Ward JF, DiBlasio CJ, Williams C, Given R, Jones JS. Cryoablation for locally advanced clinical stage T3 prostate cancer: a report from the Cryo-On-Line Database (COLD) Registry. *BJU Int.* 2014;113(5):714-718.
2. Langley S, Eden C, Perry M, Patil K, Moschonas D, Higgins D, Deering C, Laing R, Perna C, Khaksar S, Uribe-Lewis S, Uribe J. Robot-assisted salvage seminal vesicle excision for isolated recurrence after low-dose-rate prostate brachytherapy. *BJU Int.* 2022;129(6):731-736.



### Herbert Lepor, MD

In 1993, Dr. Lepor was appointed professor and chair of the Department of Urology and professor in the Department of Biochemistry and Molecular Pharmacology at NYU School of Medicine, now NYU Grossman School of Medicine. Dr. Lepor is currently chief urologist at NYU Langone Health and the Martin Spatz Chair of the Department of Urology.

Dr. Lepor received his undergraduate degree from the University of California, Los Angeles, in 1975 and his doctor of medicine degree from The Johns Hopkins University School of Medicine in 1979. He completed his surgery and urology residency training at The Johns Hopkins Hospital in 1985.

Dr. Lepor has served on the editorial boards of 4 major urological journals and has written more than 400 peer-reviewed articles, 50 book chapters, and 12 books on prostate cancer, benign prostatic hyperplasia, and the pharmacology of the prostate. He was co-founder and editor of *Reviews in Urology*. In addition, Dr. Lepor has been a visiting professor at 30 institutions.

Dr. Lepor's primary clinical and basic research interests are related to the prostate. Some of his landmark scientific contributions have focused on the identification of the autonomic intervention regulating male sexual function, the development of the nerve-sparing radical prostatectomy, the improvement of outcomes following radical retropubic prostatectomy and following focal ablation of prostate cancer, the characterization of the prostate alpha1 adrenoceptor, and the medical and surgical management of benign prostatic hyperplasia.

In 1995, Dr. Lepor was awarded the Gold Cystoscope Award by the American Urological Association. Dr. Lepor is a member of the American Association of Genitourinary Surgeons, the Clinical Society of Genitourinary Surgeons, the American Surgical Association, and the Johns Hopkins University Society of Scholars.

Our renowned [urologic specialists](#) have pioneered numerous advances in the surgical and pharmacological treatment of urologic disease.

*For questions and/or patient referrals, please contact us by phone or by e-mail.*

Faculty	Specialty	Phone Number/Email
<b>James Borin, MD</b>	Kidney stones, Kidney Cancer, Ureteral Stricture, UPJ obstruction, Endourology, Robotic Renal Surgery, Partial Nephrectomy, Ablation of Renal Tumors, PCNL	646-825-6387 james.borin@nyulangone.org
<b>Benjamin Brucker, MD</b>	Female Pelvic Medicine and Reconstructive Surgery, Pelvic Organ Prolapse-Vaginal and Robotic Surgery, Voiding Dysfunction, Male and Female Incontinence, Benign Prostate Surgery, Neurourology	646-754-2404 benjamin.brucker@nyulangone.org
<b>Seth Cohen, MD</b>	Female Sexual Dysfunction, Male Sexual Dysfunction, General Urology, Benign Disease Prostate, Post-Prostatectomy Incontinence, Erectile Dysfunction, Hypogonadism	646-825-6318 seth.cohen@nyulangone.org
<b>Christina Escobar, MD</b>	Female Pelvic Medicine and Reconstructive Surgery, Pelvic Organ Prolapse, Incontinence in Women, Female Voiding Dysfunction, Neurourology	646-825-6324 christina.escobar@nyulangone.org
<b>Frederick Gulmi, MD*</b>	Robotic and Minimally Invasive Urology, BPH and Prostatic Diseases, Male and Female Voiding Dysfunction, Kidney Stone Disease, Lasers in Urologic Surgery, and Male Sexual Dysfunction	718-630-8600 frederick.gulmi@nyulangone.org
<b>Joel Hillelsohn, MD†††</b>	Erectile Dysfunction, Peyronie's Disease, Penile Prosthesis, Hypogonadism, BPH, Kidney Stones, Male Sexual Dysfunction, Chronic Prostatitis	646-660-9999 joel.hillelsohn@nyulangone.org
<b>William Huang, MD</b>	Urologic Oncology (Open and Robotic) – for Kidney Cancer (Partial and Complex Radical), Urothelial Cancers (Bladder and Upper Tract), Prostate and Testicular Cancer	646-744-1503 william.huang@nyulangone.org
<b>Grace Hyun, MD</b>	Pediatric Urology including Hydronephrosis, Hypospadias, Varicoceles, Undescended Testicles, Hernias, Vesicoureteral Reflux, Urinary Obstruction, Kidney Stones, Minimally Invasive Procedures, Congenital Anomalies	212-263-6420 grace.hyun@nyulangone.org
<b>Matthew Katz, MD</b>	Kidney Stone Disease, Upper Tract Urothelial Carcinoma, Ureteral Stricture Disease, and BPH/Benign Prostate Disease	646-825-6387 matthew.katz@nyulangone.org
<b>Christopher Kelly, MD</b>	Male and Female Voiding Dysfunction, Neurourology, Incontinence, Pelvic Pain, Benign Prostate Disease	646-825-6322 chris.kelly@nyulangone.org
<b>Herbert Lepor, MD</b>	Prostate Cancer: Elevated PSA, 3D MRI/Ultrasound Co-registration Prostate Biopsy, Focal (Ablation) of Prostate Cancer, Open Radical Retropubic Prostatectomy	646-825-6327 herbert.lepor@nyulangone.org
<b>Stacy Loeb, MD, MSc**</b>	Urologic Oncology, Prostate Cancer, Benign Prostatic Disease, Men's Health, General Urology	718-261-9100 stacy.loeb@nyulangone.org
<b>Danil Makarov, MD, MHS***</b>	Benign Prostatic Hyperplasia, Erectile Dysfunction, Urinary Tract Infection, Elevated Prostate-specific Antigen, Testicular Cancer, Bladder Cancer, Prostate Cancer	718-376-1004 danil.makarov@nyulangone.org
<b>Meredith Metcalf, MD† ††</b>	Urologic Oncology (Open and Robotic) - Kidney Cancer, Urothelial Cancer (Bladder and Upper Tract), Testicular Cancer, Prostate Cancer	718-630-8600 meredith.metcalf@nyulangone.org
<b>Nnenaya Mmonu, MD, MS</b>	Urethral Strictures, Robotic and Open Reconstructive Surgery for Ureteral Obstruction/Stricture, Fistulas, Bladder Neck Obstruction, Penile Prosthesis, Post Prostatectomy and Radiation Urinary Incontinence	646-754-2419 nnenaya.mmonu@nyulangone.org
<b>Bobby Najari, MD</b>	Male Infertility, Vasectomy, Vasectomy Reversal, Varicocele, Peyronie's Disease, Gender Dysphoria.	646-825-6348 bobby.najari@nyulangone.org
<b>Valary Raup, MD†† ††††</b>	Male Infertility, Varicocele, Penile Prosthesis, Artificial Urinary Sphincter, Peyronie's Disease, Penile Plication, Erectile Dysfunction, Male Sexual Health, Vasectomy, Vasectomy Reversal	646-754-2000 valary.raup@nyulangone.org
<b>Nirit Rosenblum, MD</b>	Female Pelvic Medicine and Reconstructive Surgery, Voiding Dysfunction, Neurourology, Incontinence, Female Sexual Dysfunction, Pelvic Organ Prolapse and Robotic Surgery	646-825-6311 nirit.rosenblum@nyulangone.org
<b>Ellen Shapiro, MD</b>	Pediatric Urology including: Urinary Tract Obstruction (ureteropelvic junction obstruction), Vesicoureteral Reflux, Hypospadias, Undescended Testis, Hernia, Varicocele, and Complex Genitourinary Reconstruction.	646-825-6326 ellen.shapiro@nyulangone.org
<b>Gary D. Steinberg, MD</b>	Muscle-Invasive Bladder Cancer, Non-Invasive Bladder Cancer, Radical Cystectomy, Urinary Tract Reconstruction After Bladder Removal Surgery	646-825-6327 gary.steinberg@nyulangone.org
<b>Lauren Stewart, MD</b>	Female Pelvic Medicine and Reconstructive Surgery, Pelvic Organ Prolapse, Incontinence in Women, Female Voiding Dysfunction	646-825-6325 lauren.stewart@nyulangone.org
<b>Wei Phin Tan, MD</b>	Urologic Oncology – Prostate Cancer, MRI-Guided Biopsy, Kidney and Prostate Cancer Surgery, Robotic Urological Cancer Surgery, Prostate Cancer Image-guided Focal Therapy (Ablation, HIFU), and Urothelial Cancer	646-825-6321 weiphin.tan@nyulangone.org
<b>Samir Taneja, MD</b>	Urologic Oncology – Prostate Cancer (MRI-Guided Biopsy, Robotic Prostatectomy, Focal Therapy, Surveillance), Kidney Cancer (Robotic Partial Nephrectomy, Complex Open Surgery), Urothelial Cancers	646-825-6321 samir.taneja@nyulangone.org
<b>James Wysock, MD, MS</b>	Urologic Oncology – Prostate Cancer, MRI-Guided Biopsy, Kidney and Prostate Cancer Surgery, Robotic Urological Cancer Surgery, Prostate Cancer Image-guided Focal Therapy (Ablation, HIFU), and Testicular Cancer	646-754-2470 james.wysock@nyulangone.org
<b>Lee Zhao, MD</b>	Robotic and Open Reconstructive Surgery for Ureteral Obstruction, Fistulas, Urinary Diversions, Urethral Strictures, Peyronie's Disease, Penile Prosthesis, and Transgender Surgery	646-754-2419 lee.zhao@nyulangone.org
<b>Philip Zhao, MD</b>	Kidney Stone Disease, Upper Tract Urothelial Carcinoma, Ureteral Stricture Disease, and BPH/Benign Prostate Disease	646-754-2434 philip.zhao@nyulangone.org

\*at NYU Langone Hospital—Brooklyn \*\*NYU Langone Ambulatory Care Rego Park \*\*\*NYU Langone Levitt Medical †NYU Langone Ambulatory Care—Bay Ridge

††NYU Langone Ambulatory Care—Brooklyn Heights †††NYU Langone Medical Associates—Chelsea ††††Preston Robert Tisch Center for Men's Health